

***Moringa oleifera* Enhances Liver Antioxidant Status via Elevation of Antioxidant Enzymes Activity and Counteracts Paracetamol-induced Hepatotoxicity**

Uma N¹, Fakurazi S¹ & Hairuszah I²

¹ Department of Human Anatomy, ² Department of Pathology
Faculty of Medicine and Health Sciences, 43400 UPM Serdang, Selangor Malaysia

ABSTRACT

This study investigated the role of antioxidant enzyme system following crude hydroethanolic extract of *Moringa oleifera* leaves (MO) in acute paracetamol (PCM) induced hepatotoxicity. Hydroethanolic extract (80%) of MO (200 mg/kg and 800 mg/kg; p.o) was pre-administered before a single oral dose of 3 g/kg PCM intoxication to male Sprague-Dawley rats. Pre-treatment of the extract was found to have reduced lipid peroxidation level when compared to the group treated with PCM only. The level of glutathione peroxidase (GPx), glutathione-S-transferase (GST) and glutathione reductase (GR) was restored to near normal in groups that were pre-treated with MO. Histopathological studies have further confirmed the hepatoprotective activity of MO compared to group treated with PCM only. The results obtained were comparable to silymarin (200 mg/kg; p.o). The MO extract was found to have significantly protected the liver against toxicity following PCM intoxication by enhancing the level of antioxidant enzyme activity.

Keywords: Aetaminophen, hepatoprotective, hepatotoxicity, *Moringa oleifera*, paracetamol

INTRODUCTION

Paracetamol (PCM) is safe when used at therapeutic margin in treating mild to moderate pain and blocks the deterioration of pyrexia. The metabolic event of PCM is well established in a number of studies (James Mayeux & Hinson, 2003). The production of *N*-acetyl *p*-benzoquinone (NAPQI) reactive metabolites through P450 dependent mixed function oxidises is believed to initiate oxidative stress (Sumioka Matura & Yamada, 2004). Following over-

dosage or chronic intake of PCM, the glucuronidation and sulfation pathway becomes saturated and subsequently depletes the antioxidant enzyme systems such as glutathione peroxidase (GPx) and reduced glutathione (GSH). Eventually, the large formation of NAPQI and other reactive oxidant species form covalent binding with endogenous macromolecules causing cellular necrosis and possibly initiate lipid peroxidation (Basu, 2003). Therefore, maintaining the balance of these systems is crucial and may possibly serve as a major

mechanism in preventing damage due to oxidative stress (Vinayagamoorthi, Bobby & Sridhar, 2008).

There has been a positive and increased development in studies on plant natural products as a potential antioxidant agent. *Moringa oleifera* (MO) belongs to the *Moringae* family, commonly known as a drumstick tree that is native to tropical Africa and India and widely naturalised and cultivated in many countries including Malaysia (Okuda *et al.*, 2001). Almost all of the *Moringa* tree parts are edible and contain a high level of antioxidants (Anwar *et al.*, 2007). Besides being a source of nutrients (Seshadri & Nambiar, 2003), studies have also demonstrated beneficial properties of this tree such as anticoagulant activity for water and waste water treatment (Bhuptawat, Folkard & Chaudari, 2007), anti-inflammatory and antinociceptive activities (Sashidhara *et al.*, 2009) as well as wound healing property (Rathi, Bodhankar & Baheti, 2006).

In ayurvedic practice of India, MO has been used for treatment of various liver disorders (Praveen *et al.*, 1993). We have recently reported that MO may have protected the liver in hepatotoxicity via increasing the level of glutathione (Fakurazi, Nanthini & Hairuszah, 2008a; 2008b). This study is further extended to evaluate the action of MO in the event of liver intoxication. Therefore, the objective of this study is to investigate the effect of ethanolic extract of MO on the level of lipid peroxidation and antioxidant enzymes of rat liver following PCM toxicity. The action of MO is compared with silymarin, a commercially available plant natural product with hepatoprotective action. The evaluation of antioxidant status of MO will further support the claim of the hepatoprotective property of this plant and will definitely contribute to advancement of knowledge in novel therapy for liver damage.

METHODOLOGY

Plant materials

The leaves of MO were collected from Bandar Sunggala Farm, Port Dickson, Malaysia and authenticated by a plant taxonomist at the Institute of Bioscience (IBS), Universiti Putra Malaysia (UPM). A voucher specimen (SK 1561/08) was deposited at the herbarium of IBS for future reference.

Preparation of crude extract

The fresh leaves were dried for 3-4 weeks. The dried leaves were then ground into powder which and then extracted in a Soxhlet extractor using a solvent of 80% ethanol: 20% distilled water with constant shaking at room temperature overnight. The extract was then filtered and residue suspended in ethanol for 48 hours and filtered. The filtrate obtained was then concentrated in a rotary evaporator (Rotavor R-200, Buchi, Switzerland). A dark green mass was obtained and stored at -20°C until further use. The crude extract was suspended in distilled water before administration to rats on the subsequent day.

Drugs and chemicals

Acetaminophen and silymarin were purchased from Sigma-Aldrich. Alanine aminotransferase (ALT), aspartate aminotransferase (AST) and alkaline phosphatase (ALP) diagnostic kits obtained from Roche Diagnostics, Germany. Eosin and Haemotoxilin solutions was obtained from BDH, U.K. 5,5,-dithiobis-2-nitrobenzoic(DTNB) and 1-Chloro-2,4-dinitrobenzene were obtained from Fluka, Australia. Reduced glutathione was purchased from Amersco, Ohio. Glutathione Disulfide (GSSG) Reductase, $\hat{\alpha}$ -Nicotinamide adenine dinucleotide phosphate reduced tetrasodium, 2-thiobarbituric acid were purchased from Sigma, USA. BCA protein assay kit was purchased from Pierce, USA.

Experimental animals

Male Sprague Dawley rats were purchased from the Faculty of Veterinary Medicine, UPM. Male Sprague-Dawley rats weighing 200-250 g were acclimatised under control humidity with regular 12 hours light dark cycle at a temperature 28 ± 3 °C with free access to food and water for seven days before treatment. Research was conducted in accordance with the internationally accepted principles for laboratory animal use and approval to perform procedures on animals was obtained from the Animal Care Unit Committee (ACUC), Faculty of Medicine and Health Sciences, UPM.

Hepatotoxicity study design

An initial study was conducted to establish the dosage of PCM in order to obtain significant hepatocellular damage. A marked necrosis in the liver histological section was accepted as an indicator of PCM induced hepatocellular damage. Rats were divided into four groups of four animals each. Groups I, II and III were orally administered with a single dose of 1 g/kg, 2 g/kg and 3 g/kg PCM in 40% sucrose buffer to obtain evidence for liver damage. Group IV which was administered with 40% sucrose buffer was treated as control group. The rats were anaesthetised at 24 and 48 hours post-treatment. Blood was removed by cardiac puncture following ether anaesthesia. The blood samples were processed for the estimation of liver function enzymes such as alanine aminotransferase (ALT) and aspartate aminotransferase (AST). The liver function tests were carried out using diagnostic kits and were run in automated biochemistry analyzer (Roche/Hitachi 902). The enzyme level was expressed as U/l. The animals were then sacrificed and livers were immediately removed. A small section from the median lobe was preserved in 10% formal saline. The remaining liver was quickly frozen in liquid

nitrogen and stored at -80°C for further analysis.

Hepatoprotective study design

Rats were randomly divided into seven groups of 10 rats each. During 14 days of pre-treatment, rats in Groups I and II were given distilled water respectively. In Groups III and IV (test groups) rats were administered with 200 mg/kg and 800mg/kg MO in distilled water. Group V rats were administered with 200 mg/kg silymarin. Finally, Groups VI and VII (MO control groups) rats were administered with 200 mg/kg and 800 mg/kg MO respectively. On day 15, all the animals were challenged with a high dose of 3 g/kg PCM in 40% sucrose buffer orally except for rats in Groups I, VI and VII which were only given 40% sucrose buffer. The dose of PCM at 3 g/kg was chosen for this study due to the presence of significant hepatocellular necrosis. Animals were then sacrificed under ether anaesthesia at 24 and 48 hours post-treatment. The livers from all animals were collected, fixed in 10% formal saline for histological analysis. The remaining livers were processed for use in the estimation of lipid peroxidation, GPx, GR and GST activities

The treatment groups include:

- Group I = Vehicle control
(40% sucrose group)
- Group II = Hepatotoxicity control
(3 g/kg PCM)
- Group III = Plant test group
(200 mg/kg MO)
- Group IV = Plant test group
(800 mg/kg MO)
- Group V = Drug control
(200 mg/kg silymarin)
- Group VI = *Moringa* control
(200 mg/kg MO)
- Group VII = *Moringa* control group
(800 mg/kg MO)

Histopathological analysis

Tissue blocks for light microscopy were fixed in 10% formalin solution. All samples were embedded in paraffin, cut in sections of 3-4 μm thickness and stained with hematoxylin and eosin (H. & E. stain). Sections were then examined for histopathological changes following each treatment regimen.

Preparation of cytosolic liver fractions

The cytosolic fractions of the rat livers were prepared as described by Speier & Wattenberg (1975). All of the following procedures were done in 4°C. Livers were weighed and washed with 1.15 % KCl. The livers were then homogenised in 1.15 % KCl (ratio of KCl to tissue, 3:1 v/w) with a homogeniser for 5 minutes. The final volumes were recorded. An amount of 2 ml of homogenate was separated to be used for determination of glutathione content. The remaining homogenate was further centrifuged at 9000x g (7600 rpm) with ultracentrifuge centrifuge, for 20 min at 4°C. The pellet was discarded whereas the supernatant was then centrifuged again at 105 000 (24200 rpm) for 1 hour at 4°C. The supernatant (cytosolic fraction) was kept in 4 individual plastic tubes until further use for enzyme Glutathione-S-Transferase (GST), Glutathione Peroxidase (GPx) and Glutathione Reductase (GR) assay.

Determination of protein content

Protein concentration in homogenate, cytosolic fraction was determined using BCA protein kit (Pierce, USA). For this test, 0.1ml of the sample replicates was pipetted into appropriately labelled test tubes. Then, 2ml of working reagent was added into each tube and mixed well. The test tubes were then covered and incubated at 37°C for 30 minutes. After the incubation period, the test tubes were cooled at room temperature. The absorbance of all samples was measured at 562 nm within 10 minutes. The protein

concentration of each sample was determined from the standard curve

Determination of lipid peroxidation

Lipid peroxidation in the liver was ascertained by the formation of malondialdehyde (MDA) and measured by thiobarbituric acid reactive (TBARs) method previously described by Tappel and Zalkin (1959). Liver samples were washed with 0.9% NaCl and homogenised at 1 g wet tissue to 9 ml of 1.15% KCl in 0.01 M phosphate buffer pH 7.4 at 4°C. Four millilitres of homogenate were incubated for 1 hour at 37°C. The homogenate (1 ml) was added to 2ml of 7.5% trichloroacetic acid and mixed. The mixture was then centrifuged at 1000 g for 10 minutes. Two millilitre volume of supernatant was transferred into another glass tube. Then 1ml of 0.7% 2-thiobarbituric acid was added into the supernatant. The mixture was boiled in a water bath for 10 minutes. The reactants were cooled for 10 minutes and TBARs were measured at 532nm. An extinction coefficient of 156 000M⁻¹cm⁻¹ was used for calculation. The results were expressed as nmoles of MDA/g of tissue.

Determination of glutathione peroxidase activity

The activities of glutathione peroxidase (GPx) in the liver cytosol were assayed according to the method of Lawrence and Burk (1976). Cytosol was diluted 10X by adding 0.1 ml of cytosol sample into 0.9 ml 0.5 M potassium phosphate buffer, pH 7.0. From the diluted sample, 50 μl was taken out and added with 0.1ml of each 0.5M potassium phosphate buffer, pH 7.0, 10 mM EDTA, 10 mM GSH, 2 mM NADPH and 15 mM cumene hydroperoxide, 5 μl GSSG-reductase and 0.344 ml distilled water. A cuvette was placed in a spectrophotometer and disappearance of NADPH over 10 min at 340 nm was recorded. For the blank cuvette, distilled water was added instead of

the sample. An extinction coefficient of $6.22 \text{ mM}^{-1}\text{cm}^{-1}$ was used for the calculations.

Determination of glutathione reductase activity

The activities of glutathione reductase (GR) in the liver cytosol were assayed according to the method of Carlberg and Mannervik (1975). Cytosol was diluted 10X by adding 0.1 ml of cytosol sample into 0.9 ml 0.2 M Sodium phosphate buffer, pH 7.6. From the diluted sample, 20 μl was taken out and added with 0.5ml of 0.2 M Sodium phosphate buffer, pH 7.6, 0.1 ml of 10 mM GSSG, and 0.18 ml distilled water in a cuvette. The reaction was initiated by adding 0.1 ml NADPH into the cuvette and NADPH decrease in absorbance over 5 min at 340 nm was recorded. A blank was run simultaneously in the absence of enzyme activity. The extinction coefficient of β -NADPH of 6.22 milimolar was used for calculation.

Determination of glutathione-S-transferase activity

The activity of glutathione-s-transferase (GST) in the liver cytosol was assayed according to the method of Habig, Pabst & Jacoby (1974), using 1-Chloro-2,4-dinitrobenzene (CDNB) as substrate. Briefly, cytosol was diluted 10X by adding 0.1 ml of cytosol sample into 0.9 ml of 0.2 M potassium phosphate buffer, pH 7.2. From the diluted sample, 50 μl was taken out and added with 0.5 ml of 0.2 M potassium phosphate buffer, 0.1ml of 10mM GSH, 0.01 of 0.1 M 1-Chloro-2,4-dinitrobenzene (CDNB) as substrate and 0.39 ml of distilled water in a semicuvette and mixed. The blank consisted of 0.55 ml of 0.2 M potassium phosphate buffer, 0.1 ml of 10mM GSH, 0.01 ml of 0.1 M 1-Chloro-2, 4-dinitrobenzene (CDNB) as substrate and 0.39 ml distilled water. The absorbance of the samples was read against the blank at 340 nm for 10 minutes using a spectrophotometer. The

changes of A340nm per minute obtained using the maximumlinear rate for both test and blank

Statistical analysis

Data was presented with mean \pm SEM. Statistical analysis was performed using ANOVA Statistical Package for the Social Sciences (SPSS) version 13.0. Differences were significant when the *P* value was less than 0.05 ($p < 0.05$). For the post-test, Tukey Multiple Comparison test was used.

RESULTS

Hepatotoxicity study

The activity of ALT and AST following 1 g/kg, 2 g/kg and 3 g/kg is shown in Table 1. There was a dose dependent increase in liver enzymes following PCM treatment. The high dose (3 g/kg) group of PCM significantly elevated both enzymes. Exposure of rats to various doses of PCM induced hepatocellular necrosis with infiltration of inflammatory cells such as lymphocytes and neutrophils. The injury observed was found to be time and dose-dependent. The hepatocytes changes following low dose (1 g/kg) of PCM was subtle, with some lymphocytes infiltration and scattered fatty changes. However, all these changes were not significant when compared to the liver sections obtained from the control rats. Treatment of high dose of PCM induced significant hepatocellular injury at 48 hours post treatment. The liver section showed centrilobular necrosis with lymphocytes and neutrophils infiltration and some microvesiculation fatty changes.

Hepatoprotective study

The biochemical parameter analysed in this study is shown in (Table 2). The high dose (3g/kg) paracetamol treatment significantly elevated lipid peroxidation measured as malondialdehyde production compared to control animals. Treatment of MO at both

Table 1. Changes in AST and ALT activities of the treatment and control groups

Treatment group	Time (h)	ALT (IU/L)	AST (IU/L)
Vehicle control40% sucrose buffer	24	68.97 ± 4.29	111.17 ± 7.15
	48	55.32 ± 6.09	121.22 ± 10.04
Low dose 1 g/kg PCM	24	56.18 ± 6.49	128.17 ± 8.63
	48	67.73 ± 9.83	166.66 ± 4.12
Medium dose2 g/kg PCM	24	90.73 ± 10.76	242.53 ± 22.03*
	48	190.78 ± 43.18*	381.42 ± 34.41*
High Dose3 g/kg PCM	24	132.97 ± 4.19*	440.38 ± 20.87*
	48	227.00 ± 10.20*	721.88 ± 83.82*

* $p < 0.05$ significantly different from group treated with 40% sucrose

doses significantly decreased lipid peroxidation following PCM treatment. Similar results were found with silymarin pre-treatment. There was comparable inhibition in MDA production when the animals were pre-treated with silymarin.

The levels of antioxidant enzymes such as glutathione peroxidase (GPx), glutathione-S-transferase (GST) and glutathione reductase (GR) were reduced following 3 g/kg PCM. The level of glutathione peroxidase was significantly reduced at the beginning of 24 hours and subsequently through 48 hours post-treatment compared to the vehicle control group. Pre-treatment at both doses of MO extract prior to PCM challenge showed a significant increase in the level of GPx activity at 24 and 48 hours compared to hepatotoxicity induced group ($p < 0.05$) (Table 2).

Similarly, the level of GST was significantly reduced ($p < 0.05$) in rats challenged with PCM compared to all treatment groups especially after 48 hours. When rats were pre-treated with MO prior to PCM challenge, enzyme activity was significantly elevated compared to the hepatotoxicity and vehicle control groups (Table 2).

However, no significant difference was found in the level of GR in rats from different

groups at 24 hours. In contrast, after 48 hours, GR activity was significantly reduced ($p < 0.05$) in rats given 3 g/kg PCM alone, when compared to all other groups. When rats were pre-treated with 200 mg/kg and 800 mg/kg MO prior to PCM, the changes in GR activity remained insignificant at 24 hours. After 48 hours, the level was significantly higher compared to groups administered with PCM alone. Histopathological examination revealed parallel findings with biochemical alteration in the liver. In the PCM treated group, severe histopathological changes such as the hallmark of PCM toxicity, centrilobular necrosis, fatty changes and infiltration of lymphocytes and neutrophils were observed (Figures 1a and 1b).

Pre-treatment of MO at both doses significantly prevented the hepatocellular changes associated with PCM intoxication. The histopathological lesion was not evident in these groups. The liver histology was observed to be similar to those animals in the control groups (Figures 2a, 2b, and 3a). Meanwhile, the hydroalcoholic extract of MO alone did not induce hepatocellular damage when the rats were administered with 200 mg/kg of MO (results not shown). Even the administration of 800 mg/kg MO did not induce any morphological changes (Figure 3b).

Table 2. Changes in lipid peroxidation and antioxidant enzymes activities of the treatment and control groups

Treatment group	Time (h)	lipid peroxidation nmol/g	(GPx) nmol/min/mg protein	(GST) nmol/min/mg protein	(GR) nmol/min/mg protein
Group I (Vehicle control)	24	26.20 ± 0.95	163.24 ± 6.19	277.83 ± 4.04	57.08 ± 0.64
	48	26.45 ± 1.07	158.41 ± 1.24	288.26 ± 3.99	59.35 ± 0.80
Group II (Hepatotoxicity control)	24	36.09 ± 1.01*	112.09 ± 2.88*	248.30 ± 6.21	54.22 ± 3.50
	48	41.98 ± 0.74 ^a	61.47 ± 7.50 ^a	197.35 ± 2.53 ^a	42.69 ± 0.84*
Group III (200 mg/kg MO)	24	29.48 ± 0.77 ^b	216.21 ± 19.74 ^{*b}	326.12 ± 2.87*	56.73 ± 0.81
	48	27.69 ± 0.32 ^b	210.24 ± 7.78 ^{*b}	319.97 ± 4.24*	85.71 ± 7.71 ^{*ab}
Group IV (800 mg/kg MO)	24	31.84 ± 0.10 ^b	183.41 ± 11.61 ^{*b}	333.14 ± 6.79*	56.56 ± 1.84
	48	28.73 ± 0.99 ^b	198.61 ± 10.99 ^{*b}	327.94 ± 5.40*	74.71 ± 1.71 ^{*ab}
Group V (Drug control: silymarin)	24	28.73 ± 0.89 ^b	171.39 ± 4.94 ^b	290.69 ± 4.46	61.38 ± 2.06
	48	29.33 ± 0.71 ^b	203.05 ± 13.98 ^{*b}	338.72 ± 9.07*	73.97 ± 3.43 ^{*ab}
Group VI (200 mg/kg MO control)	24	25.67 ± 0.58 ^b	181.92 ± 12.65	304.50 ± 9.73	63.75 ± 1.48
	48	27.14 ± 0.44 ^b	189.64 ± 7.50	300.63 ± 5.95	65.34 ± 1.77
Group VIII (800 mg/kg MO control)	24	26.76 ± 0.42 ^b	171.20 ± 1.95	302.37 ± 7.59	64.78 ± 4.72
	48	27.17 ± 0.36 ^b	173.91 ± 3.23	304.75 ± 7.83	63.12 ± 2.82

* $p < 0.05$; significantly different from group treated with vehicle control group

^a $p < 0.05$; significantly different from hepatotoxicity control group at 24 h

^b $p < 0.05$; significantly different from hepatotoxicity control at respective time points

DISCUSSION

Our study has demonstrated that pre-treatment of rats with MO prevented biochemical and pathological alteration induced by the PCM. The dose of 3 g/kg PCM was chosen in this study based on the results obtained earlier. The results obtained following 3 g/kg PCM were consistent with previous studies (Ajith, Hema & Aswathy, 2007; Kumar *et al.*, 2004).

The leakage of ALT and AST into plasma indicates hepatic injury or damage (Kumar *et al.*, 2004). The largest pool of ALT was found in the hepatic parenchymal cells of the liver (Amacher, 1998). Meanwhile, AST was found in cardiac muscle, skeletal muscle, pancreas and kidney (Amacher, 1998; Shyamal *et al.*, 2006). Although measurement of ALT is regarded as more liver specific to test hepatocellular damage (Shyamal *et al.*, 2006), AST is still being

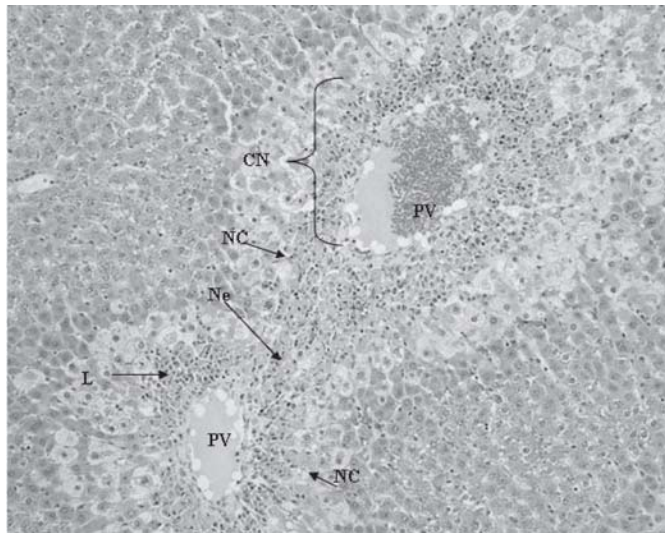


Figure 1a. Photomicrograph shows liver section from rat treated with 3g/kg PCM sacrificed after 24 hours post-treatment. The section demonstrates presence of inflammation with recruitment of numerous lymphocytes (L) and neutrophil infiltration (N) and severe necrosis diffuse but confined to perivenular area , necrotic hepatocytes. Magnification 100x. PV: Perivenular, NC: Necrotic hepatocytes

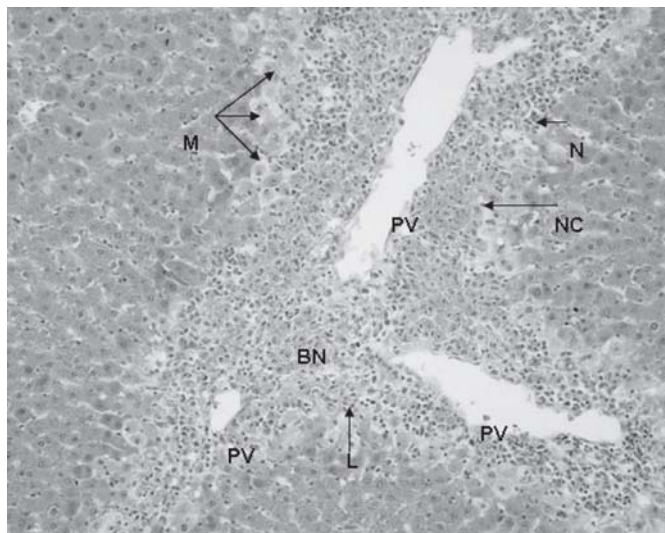


Figure 1b. Photomicrograph shows liver section from rat treated with 3 g/kg PCM sacrificed 48 hours post-treatment. Liver section demonstrates presence of massive inflammation with numerous lymphocyte infiltration (L) and neutrophills (N), Necrotic hepatocytes, and bridging necrosis (BN) around perivenular area around PV. Magnification 100x. PCM: Paracetamol, PV: Perivenular

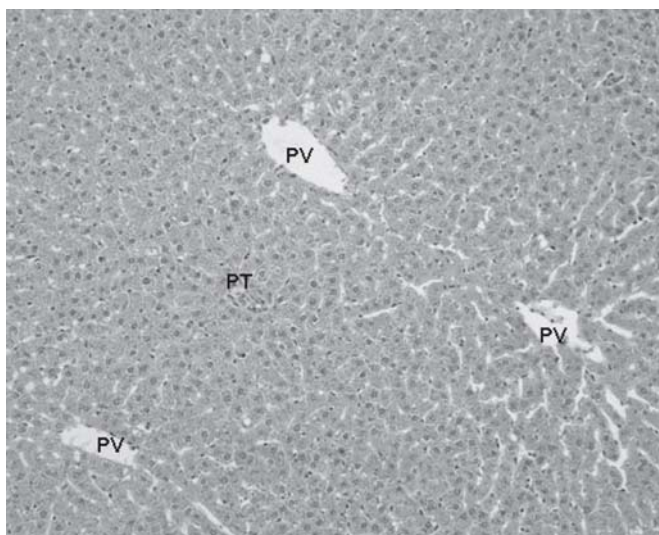


Figure 2a. Photomicrograph shows liver section from rat pretreated with 200 mg/kg MO extract prior to PCM sacrificed 24 hours post-treatment. Most of the PV area is well preserved. Magnification: 100x. MO: *Moringa oleifera*, PV: Perivenular , PT: Portal tract

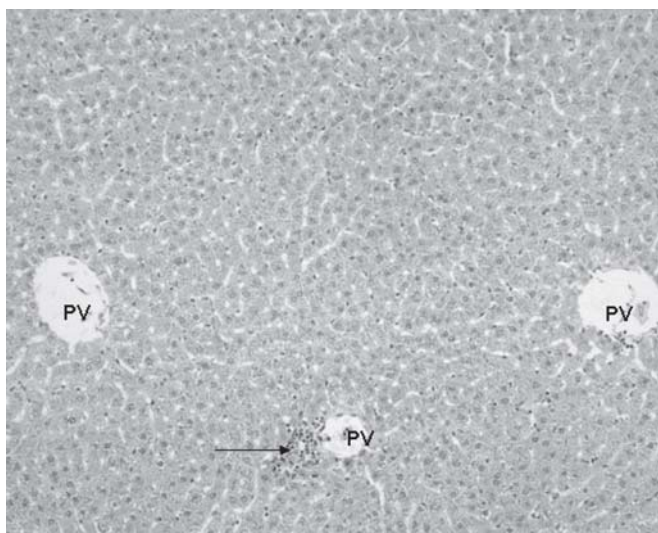


Figure 2b. Photomicrograph shows liver section from rat pretreated with 800 mg/kg MO extract prior to PCM sacrificed after 24 hours post-treatment. Most of the PV area is well preserved and some focal infiltration of lymphocyte (→) around PV is observed. Magnification: 100x. PCM: Paracetamol, MO: *Moringa oleifera*, PV: Perivenular

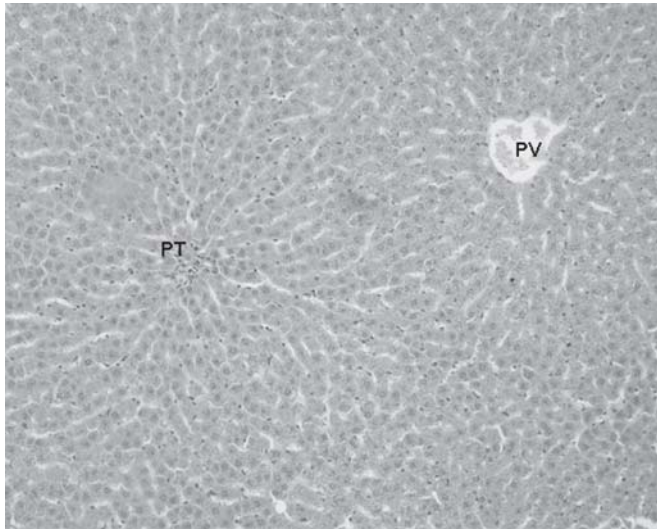


Figure 3a. Photomicrograph shows liver section of rat pretreated with 200 mg/kg MO prior to PCM sacrificed 48 hours post-treatment. The section reveals presence of normal hepatocytes with absence of infiltration of inflammatory cells around perivenular area and portal tract Magnification: 100x. PCM: Paracetamol, PV: Perivenular area, PT: Portal tract

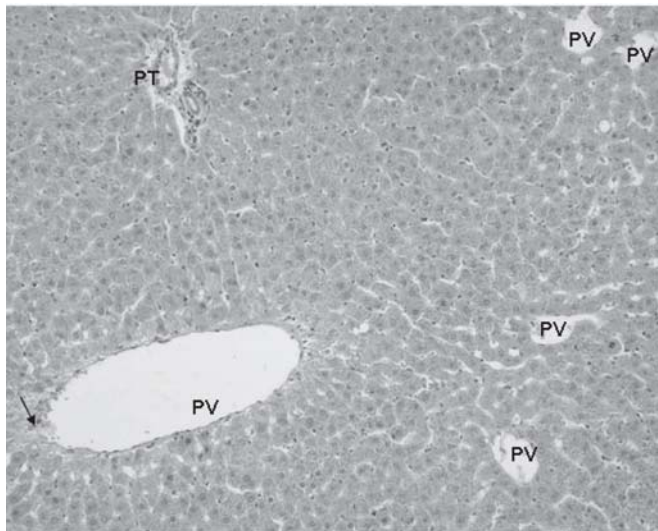


Figure 3b. Photomicrograph shows liver section from rat pretreated with 800 mg/kg MO extract sacrificed after 48 hours. The section demonstrated normal architecture of hepatocytes, focal hydropic degeneration (à) around PV area. Infiltration of monocytes and neutrophils was absent around PV. Hepatocytes around PT appears to be normal. Magnification: 100x. MO: *Moringa oleifera*, PV: Perivenular, PT: Portal tract

commonly used to assess liver function since it is considered to be a sensitive indicator of mitochondria damage particularly in the centrilobular region of the liver (Amacher, 1998). Our study has demonstrated that the high dosage of PCM induced hepatocellular damage causing leakage of AST and ALT into the circulation that is normally cytoplasmic in location.

Over-dosage of PCM leads to centrilobular necrosis, fatty infiltration, lymphocytic and neutrophil infiltration (Yen *et al.*, 2007). In this study, administration of PCM led to prominent bridging necrosis, seen around the centrilobular area. This may possibly be due to the metabolism of PCM which involves the cytochrome P450 system that is abundantly distributed in Zone 3-centrilobular region (Z3). The dominant distribution of CYP450 in Z3 inflicts localised production of reactive metabolites of PCM which is responsible for inducing hepatic necrosis around this area (Chung *et al.*, 2004). In our study the administration of 2 g/kg PCM showed a moderate necro-inflammatory score and elevation of plasma transaminase levels which is in contrast to previous findings (Yanpallewar *et al.*, 2002; Asha *et al.*, 2004). Consequently, the dose of 3 g/kg PCM was chosen for hepatotoxicity study in order to induce more prominent liver damage.

Over dosage of paracetamol (PCM) leads to increased generation of reactive oxygen species (ROS) due to excessive production of NAPQI (James *et al.*, 2003; Yen *et al.*, 2007). The high level of ROS is known to cause impairment of antioxidant enzyme activities and substantially leads to oxidative stress. Oxidative stress in turn induces various deleterious actions including lipid peroxidation, which is characterised by oxidative degeneration of membrane (Yen *et al.*, 2007). We observed this phenomenon in the recent study in the group which was administered with PCM only. Induction of hepatotoxicity by ROS can be prevented

following the administration of an agent with antioxidant capacity (Attri *et al.*, 2000).

Following administration of PCM, there was a significant reduction in the activities of glutathione peroxidase (GPx), glutathione-S-transferase (GST) and glutathione reductase (GR) (Arnaiz *et al.*, 1995; Ahmed and Khater 2001; Jodynis-Liebert *et al.*, 2005). This shows that endogenous antioxidant activity is impaired by a high dose of PCM. Concurrently, there was also an elevation of lipid peroxidation activity which coincided with oxidative stress and capability of inducing hepatotoxicity (Jodynis-Liebert *et al.*, 2005). GST is an antioxidant and phase II metabolising enzyme which plays a critical role in hindering the formation of PCM adducts with cellular macromolecules. It promotes the elimination of NAPQI toxic reactive metabolites by catalyzing conjugation with reduced glutathione (GSH) (Ahmed & Khater 2001; Jodynis-Liebert *et al.*, 2005). In this study, the protective effect of MO was evident when the enhancement of GST level was observed in rats given MO in combination with PCM. MO extract alone did not affect the activity of GST nevertheless; the compounds within the MO extract may have induced GST activity with the presence of a hepatotoxin. Similar results were reported for some hepatoprotective plants like *Aquilegia vulgaris*, *Ambrosia maritime* and *Zingiber officinale* which showed induction of GST level following the administration of plant extract together with PCM, rather than the administration of the extract alone (Ajith *et al.*, 2007; Ahmed & Khater, 2001; Jodynis-Liebert *et al.*, 2005). A significantly higher level of GST activity in rats pre-treated with MO extract compared to sucrose treated rats, suggested the capacity of MO to rapidly detoxify reactive toxic metabolites of PCM and protect the liver from drug induced toxicity. In addition, the MO extract appeared to have a more superior effect than silymarin, evident in a more prominent

induction of GST activity in rats pre-treated with MO compared to those administered with silymarin.

Pre-treatment of MO extracts has also reversed the reduction of GPx by PCM. The enhancement of enzyme activity was only prominent when MO extracts were given together with PCM. The role of GPx against PCM-mediated hepatotoxicity could partly be explained by the ability of the plant to prevent activity impairment. It has effectively scavenged the occurrence of free radicals generated during PCM metabolism and subsequently reduced the destructive effects of oxidative stress. The results revealed that a MO dose at 200 mg/kg MO may be better than 800mg/kg MO, as evidenced by enhancement of the GPx activity in the PCM treated group up to the level higher than the vehicle group after 24 hours.

Meanwhile, GR is essential in maintaining adequate hepatic GSH level by facilitating the regeneration of GSH from oxidised glutathione (GSSG) (Ahmed & Khater, 2001). The protective effect of MO was also reflected in the induction of GR activity by MO extract given prior to PCM challenge. Although the substance itself did not increase GR activity, the activity was increased with MO supplementation prior to PCM challenge. This showed that the reduction in the activity of the enzyme was prevented following MO pre-treatment. However, the activity was only induced after 48 hours. Collectively, the hepatoprotective property of MO could also be explained in terms of enhancement of GR activity supporting the endogenous GSH pool allowing the cell to detoxify more NAPQI and other free radicals, subsequently minimising hepatocytes damage. Crude MO is comparable to silymarin in triggering GR activity, which is also further suggestive of the potential role of the extract as a hepatoprotective agent.

The benefits of MO extract are confirmed by histopathological observations. The hepatoprotective effect of MO pretreatment

was observed when the extract was administered to rats before PCM overdose. Centrilobular necrosis, the hallmark feature of APAP-induced liver damage was significantly reduced with MO pre-treatment (Oliveira *et al.*, 2005). The presence of congestion and inflammatory cells infiltration evoked by PCM was considerably decreased following MO extract pre-treatment. The ability of MO to reverse the hepatic lesions induced by the PCM to a large extent is comparable to the treatment with sucrose and silymarin, and is highly suggestive of the hepatoprotective effect of MO.

It has been reported that enhanced lipid peroxidation induced by antitubercular drug treatment accompanied by a significant decrease in GPx, and GST was reversed by administration of MO extract (Kumar & Pari, 2003). Our results are consistent with a previous study in which administration of MO showed protection against lipid peroxidation with enhancement of GPx, GR and GST activity. The quick detoxification of reactive metabolites by GST, reduction of lipid peroxide action by GPx as well as the role of GR in restoration of reduced glutathione level from GSSG could partly explain the protective effect of MO extract against PCM induced oxidative stress subsequently inhibiting lipid peroxidation. The liver protective action offered by the extract against oxidative damage is strongly supported by preservation of liver architecture revealed by the histopathological study.

On the other hand, reports have shown methanol and ethanol MO extract to demonstrate significant *in vitro* radical scavenging activity (Siddhuraju & Becker, 2003). Apart from this, phytochemical analysis has revealed the presence of natural antioxidants in MO extracts such as phenolics compounds including flavonoid groups such as quercetin and kaempferol. It was also reported that the antioxidant potential of quercetin was comparable to that

of vitamin E (Bramley & Pridham, 1995). Thus the ability of MO itself to act as a free radical scavenger by trapping ROS and hindering interaction with polyunsaturated fatty acids could also possibly rationalise inhibition of lipid peroxidation by MO extract.

CONCLUSION

The present study has demonstrated that the hydroethanolic extract of MO has hepatoprotective effect against PCM induced hepatotoxicity in rats. Our results strongly support the traditional claim of this plant for hepatoprotective action. The preservation of antioxidant enzymes and decreased formation of lipid peroxidation are suggestive of its protective mechanism of MO extract in preventing PCM induced liver damage. Further investigations on the presence of bioactive compounds should be conducted to further substantiate the hepatoprotective effect of the plant product which may prove useful for human consumption.

ACKNOWLEDGEMENTS

The authors would like to acknowledge the contribution of Dr Abdah Md Akim, Ms Aimi and Ms Syazana who provided technical assistance in generating the project and manuscript.

REFERENCES

Ahmed MB & Khater MR (2001). Evaluation of the protective potential of *Ambrosia* maritime extract on acetaminophen-induced liver damage. *J Ethnopharmacol* 75: 169-174.

Ajith TA, Hema U & Aswathy MA (2007). *Zingiber officinale* Roscoe prevents acetaminophen-induced acute hepatotoxicity by enhancing hepatic anti-

oxidant status. *Food Chem Toxicol* 45(11): 2267-72.

Amacher DE (1998). Serum transaminase elevations as indicators of hepatic injury following the administration of drugs. *Regulatory Toxicol Pharmacol* 27: 119-130.

Anwar F, Latif S, Ashraf M & Gilani AH (2007). *Moringa oleifera*: a food plant with multiple medicinal uses. *Phytother Res* 21(1): 17-25.

Arnaiz LS, Lesuy S, Cutrin JC & Boveris A (1995). Oxidative stress by acute acetaminophen administration in mouse liver. *Free Radical Biol Medicine* 19: 303-310.

Asha VV, Akhila S, Wills PJ & Subramoniam A (2004). Further studies on the antihepatotoxic activity of *Phyllanthus maderaspatensis* Linn. *J Ethnopharmacol* 92: 67-70.

Attri S, Rana SV, Vaiphei K, Sodhi CP, Katyals R, Goel RC, Nain CK & Singh K (2000). Isoniazid- and rifampicin-induced oxidative hepatic injury – protection by N-acetylcysteine. *Hum Exp Toxicol* 19(9): 517-22.

Basu S (2003). Carbon tetrachloride-induced lipid peroxidation: eicosanoid formation and their regulation by antioxidant nutrients. *Toxicology* 189(1-2): 113-127.

Bhuptawat H, Folkard GK & Chaudhari S (2007). Innovative physico-chemical treatment of wastewater incorporating *Moringa oleifera* seed coagulant. *J Hazard Matter* 142(1-2):477-482.

Bramley PM & Pridham JB (1995). The relative antioxidant activities of plant derived polyphenolic flavonoids. *Free Radical Res* 4: 375-383.

- Carlberg I & Mannervik B (1975). Purification and characterization of the flavoenzyme glutathione reductase from rat liver. *J Biol Chem* 250: 5475.
- Chung YH, Kim JA, Song BC, Song IH, Koh MS, Lee HS, Yu E, Lee YS & Su DJ (2001). Centrilobular hepatic necrosis; isocitrate dehydrogenase as a marker of centrilobular model of rats. *J Gastroenterol Hepatol* 16: 328-332.
- Fakurazi S, Nanthini U and Hairuszah I (2008). Hepatoprotective and antioxidant action of *Moringa oleifera* Lam Against acetaminophen induced hepatotoxicity in rats. *Int J Pharmacol* 4(4): 270-75.
- Fakurazi S, Hairuszah I and Nanthini U (2008). *Moringa oleifera* Lam prevents acetaminophen induced liver injury through restoration of glutathione level. *Food Chem Toxicol* 46: 2611-15.
- Habig WH, Pabst MJ & Jacoby WB (1974). Glutathione-S-transferases the first step in mercapturic acid formation. *J Biol Chem* 249: 7130-139.
- James LP, Mayeux PR & Hinson JA (2003). Acetaminophen-induced hepatotoxicity. *Drug Metab Dispos* 31(12): 1499-1506.
- Jodynis-Liebert J, Matławska I, Bylka W & Murias M (2005). Protective effect of *Aquilegia vulgaris* (L.) on APAP-induced oxidative stress in rats. *J Ethnopharmacol* 97: 351-358.
- Kumar G, Banu GS, Pappa PV, Sundararajan M & Pandian MR (2004). Hepatoprotective activity of *Trianthema portulacastrum* L. against paracetamol and thioacetamide intoxication in albino rats. *J Ethnopharmacol* 92(1): 37-40.
- Kumar NA & Pari L (2003). Antioxidant action of *Moringa oleifera* Lam. (Drumstick) against antitubercular drugs induced lipid peroxidation in rats. *J Med Food* 6(3): 255-259.
- Lawrence RA & Burk RF (1976). Glutathione peroxidase activity in selenium deficient rat liver. *Biochem Biophys Res Comm* 71: 952.
- Okuda T, Baes AU, Nishijima W & Okada M (2001). Isolation and characterization of coagulant extracted from *Moringa oleifera* seed by salt solution. *Water Res* 35: 405-410.
- Oliveira FA, Chaves MH, Almeida FRC, Lima RCP, Silva RM, Maia JL, Brito GA, Santos FA & Rao VS (2005). Protective effect of α - and β -amyrin, a triterpene mixture from *Protium heptaphyllum* (Aubl.) March. trunk wood resin, against acetaminophen-induced liver injury in mice. *J Ethnopharmacol* 98: 103-108.
- Praveen RB, Kokate CK, Rambhau D, Venkateshwarlu V & Murthy VN (1993). Antihepatotoxic activity of some ayurvedic preparations. *Indian J Pharm Sci* 55: 137-140.
- Rathi BS, Bodhankar SL & Baheti AM (2006). Evaluation of aqueous leaves extract of *Moringa oleifera* Lam for wound healing in albino rats. *Indian J Exp Biol* 44(11): 898-901.
- Sashidhara KV, Rosaiah JN, Tyagi E, Shukla R, Raghubir R & Rajendran SM (2009). Rare dipeptide and urea derivatives from roots of *Moringa oleifera* as potential anti-inflammatory and antinociceptive agents. 44(1): 432-6.
- Seshadri S & Nambiar VS (2003). Kanjero *Digera arvensis* and drumstick leaves

- (*Moringa oleifera*): nutrient profile and potential for human consumption. *World Rev Nutr Diet* 91: 41-59.
- Shyamal S, Latha PG, Shine VJ, Suja SR, Rajasekharan S & Devi TG (2006). Hepatoprotective effects of *Pittosporum neelgherrense* Wight&Arn., a popular Indian ethnomedicine. *J Ethnopharmacol* 107:151-155.
- Siddhuraju P & Becker K (2003). Antioxidant properties of various solvent extracts of total phenolic constituents from three different agroclimatic origins of drumstick tree (*Moringa oleifera* Lam.) leaves. *J Agric Food Chem* 51: 2144-2155.
- Speier CL & Wattenberg LW (1975). Alterations in microsomal metabolism of benzo (α)-pyrene in mice fed butylate hydrxyanisole. *J Natl Cancer Inst* 55: 469-472.
- Sumioka I, Matsura T & Yamada K (2004). Acetaminophen-Induced hepatotoxicity: still an important issue. *Yonago Acta medica* 47: 17-28.
- Tappel AL & Zalkin H (1959). Inhibition of lipid peroxidation in mitochondria by vitamin E. *Arch. Biochem Biophys* 80: 333-336.
- Vinayagamoorthi R, Bobby Z & Sridhar MG (2008). Antioxidants preserve redox balance and inhibit c-Jun-N-terminal kinase pathway while improving insulin signaling in fat-fed rats: evidence for the role of oxidative stress on IRS-1 serine phosphorylation and insulin resistance. *J Endocrinol* 197(2): 287-296.
- Yanpallewar SU, Sen S, Tapas S, Kumar M, Raju SS & Acharya SB (2003). Effect of *Azadirachta indica* on paracetamol-induced hepatic damage in albino rats. *Phytomedicine* 10(5): 391-396.
- Yen FL, Wu TH, Lin LT & Lin CC (2007). Hepatoprotective and antioxidant effects of *Cuscuta chinensis* against acetaminophen-induced hepatotoxicity in rats. *J Ethnopharmacol* 111: 123-128.